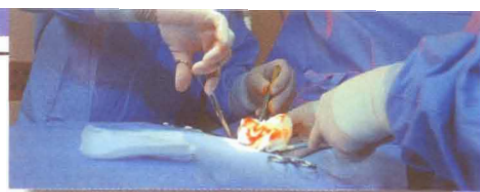

# Surgical Pearls

By Richard T. Braver, DPM



## EVERYTHING YOU NEED TO KNOW ABOUT TARSAL TUNNEL SURGERY

One of the most perplexing dilemmas for podiatrists is tarsal tunnel syndrome (TTS). Defined as a compression injury of the posterior tibial nerve within the tarsal tunnel, TTS appears to be more prevalent in athletes, overweight individuals and people who stand for long periods of time. Indeed, even the most seasoned podiatrist may have difficulty diagnosing this condition.

After all, patient complaints may include feeling weakness at the bottom of the foot, a sense of fullness of the arch, and burning pains along the medial ankle and plantar foot. The symptoms of TTS can range from an ache in the medial ankle/arch to tingling/electrical shock sensations in this area. The condition is often misdiagnosed as concomitant posterior tibial tendonitis or plantar fasciitis. However, these problems—which are typically worse in the morning or when patients get up after a period of rest—gradually improve when patients stretch.

Patients with TTS usually have more arch pain with a burning sensation. Until patients complain of shooting electrical shocks, the diagnosis of TTS is frequently overlooked.

Conservative treatment can be equally frustrating. More often than not, these patients don't tolerate or respond to orthotics. Likewise, the use of physical therapy modalities, cast immobilization, NSAIDs or corticosteroid injections may only provide temporary relief. If this is the case, then you need to take a look at surgical solutions.

### How To Get Started

When it comes to functional tarsal tunnel syndrome, you want to perform the surgical procedure without a tourniquet in order to clearly see the pulsations of the posterior tibial artery. Draw an incision line over and along the palpated pulsations of this artery. Your incision should extend from just above the medial malleolus and

proceed distally toward the inferior aspect of the navicular bone.

Carefully cut through the skin and then deepen the incision, using a Metzenbaum scissor and scalpel. Then use the wet sponge technique to reflect the subcutaneous tissues away from the covering of the tarsal tunnel (a.k.a. lacinate ligament). Carefully transect this ligament along the course of the neurovascular bundle in line with your initial incision. Keep an eye out for the medial calcaneal nerve which perforates through the lacinate ligament to innervate the skin at the medial and plantar heel.

At this point, you should have a clear view of the posterior tibial artery with the venae comitantes on each side. Keep in

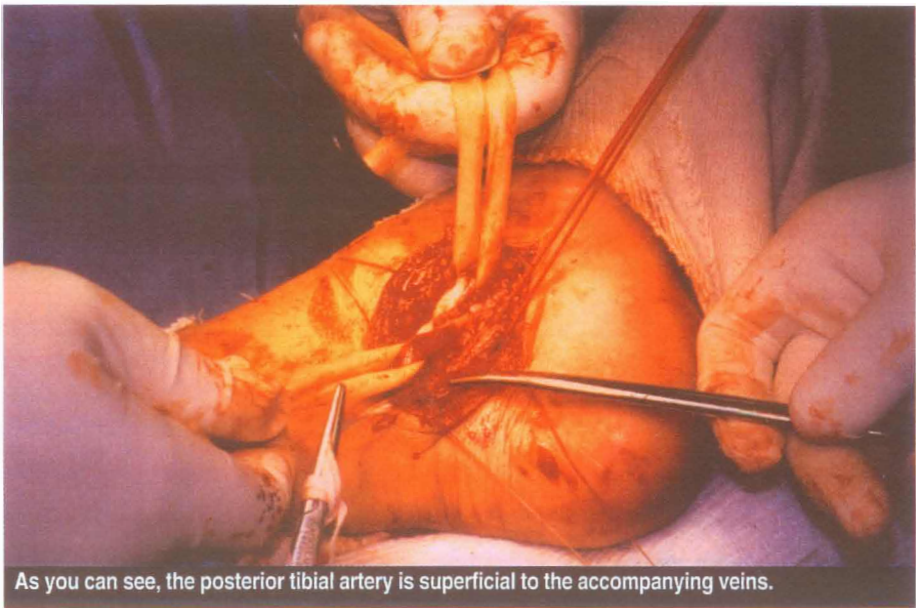
mind that this artery is often raised and more superficial than its accompanying veins. Retract the artery and veins and you will see the posterior tibial nerve below. Carefully dissect along this structure, freeing it from possible adhesions.

During dissection, if you see varicose or tortuous veins crossing over or branching from the venae comitantes, and you feel that they may impinge upon the nerve when they're engorged with blood, you should cauterize or ligate them.

### What To Look For Around The Posterior Tibial Nerve

Examine the posterior tibial nerve distally where it splits into the medial and lateral nerve branches. Keep in mind that this nerve should pass through the opening (porta pedis) in the abductor hallucis muscle. To ensure that it is free of adhesions, insert a closed Metzenbaum scissor, Freer elevator or other blunt instrument through the canal.

Sometimes, you'll need to transect the covering sheath of the abductor hallucis muscle to allow for decompression of the porta pedis/posterior tibial nerve. Check to make sure there are no abnormalities to this nerve, such as a thickened sheath or soft tissue mass. Make sure you biopsy any suspicious pathology. You

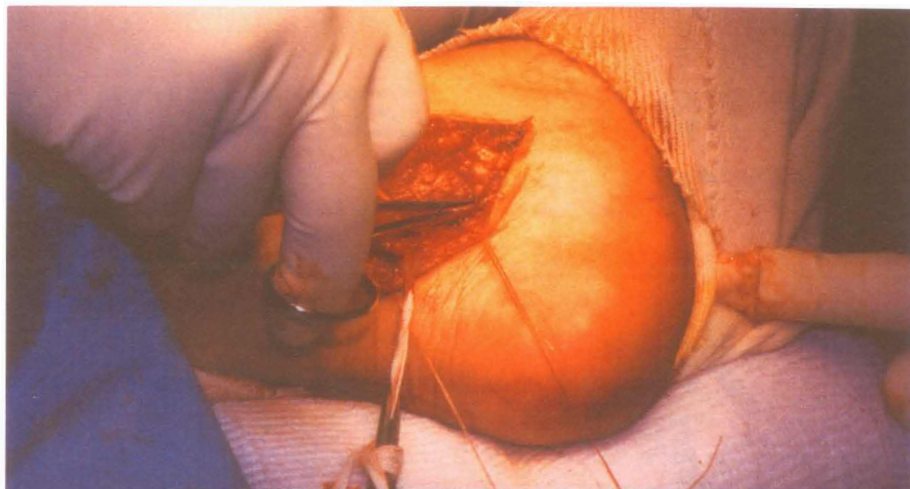


As you can see, the posterior tibial artery is superficial to the accompanying veins.

should also palpate the medial aspect of the talus to make sure it is not enlarged. If it's enlarged, rasp the area smooth as it may impinge upon the tarsal canal contents.

More often than not, tarsal tunnel pain is a result of a tendon abnormality. Make sure you have a clear, direct view of the anatomy. Don't forget to check for accessing muscles or tendons. To examine the tendons, direct your attention to the medial malleolus, making a longitudinal incision between the tendons of the posterior tibial and flexor digitorum longus. You'll often find that this one incision opens up the sheaths of both tendons. Proceed to examine these tendons thoroughly for ganglionic growth, longitudinal tears and other irregularities.

Then proceed with further dissection to the flexor hallucis longus tendon, which is inferior to the neurovascular bundle. You'll often see a hypertrophied muscle here instead of a tendon in this area. This is especially the case among dancers and athletes who frequently rise up on their toes. Sometimes, you'll need to surgically thin this muscle mass. If it is slightly enlarged, then the release of the lacinate ligament is enough to decompress



It is important to free up the porta pedis opening within the abductor hallucis muscle.

this structure.

You should carefully examine the flexor hallucis tendon by flexing and extending the big toe joint. Also palpate the posterior aspect of the talus with your finger so you can determine whether there is a sharp lateral process of the posterior talus (Steida's process) or prominent os trigonum. You may have to smooth or excise this bone as it may contribute to functional tarsal tunnel pain by irritating

the flexor hallucis longus tendon. On several occasions, this bone has been the sole culprit for posterior and/or medial ankle tarsal tunnel pain.

## Final Notes

Irrigate the surgical site with saline solution. Check for any bleeding vessels that need to be cauterized. You should use an absorbable suture in horizontal mattress suturing technique to close the sheaths overlying the posterior tibial flexor digitorum longus tendons. Loosely reapproximate the lacinate ligament and do not suture it. Perform a subcutaneous closure with 2-0 absorbable suture. You may perform the skin closure by using a running subcuticular suturing technique.

Anesthetize the posterior tibial tendon with 0.5% Bupivacaine solution. Apply sterile gauze bandages and place the patient in a posterior splint cast. Have the patient wear the cast for up to three weeks, non-weightbearing, prior to initiating rehabilitative therapy. ■

## The Mysterious Etiology Of Tarsal Tunnel

Consider the varied etiology of TTS. Some physicians equate this nerve compression injury to a mini-compartment syndrome. The problem can be caused by anything that causes compression upon the nerve: previous trauma with resultant nerve injury or fibroses; subtalar joint tarsal coalition or bone spurs and cysts impinging on the nerve; tenosynovitis of adjacent tendons; edematous ankles/venous insufficiency and varicose veins within the tarsal tunnel; or accessory and hypertrophied muscles (seen in athletes) within the tarsal tunnel.

Also keep in mind that systemic diseases can be the cause of vascular or arthritic changes, which have detrimental effects upon the nerve. Furthermore, chronic strain of the nerve and tendons through excessive foot pronation can lead to microtrauma. Finally, problems can stem from anatomic variations, which could range from a narrowing of the adductor hallucis canal thru which the nerve passes to a tight covering of the tarsal tunnel (often referred to as the lacinate ligament or flexor retinaculum).

So what diagnostic tests should you use? Use X-rays for osseous deformities, an MRI for accessory muscles, soft tissue tumors and other abnormalities, and consider the use of nerve conduction tests (NCTs). The latter testing method is often reassuring when it's positive, but a normal study does not negate the diagnosis of TTS. When you have a patient exercise prior to the NCT, it causes the foot muscles and varicose veins to engorge with blood, which has increased the rate of positive test results.

However, taking a clinical history and performing a routine examination will still provide the most important findings. This is especially the case when there is a positive Tinel's sign upon percussion of the posterior tibial nerve.

*Dr. Braver is board certified in foot and ankle surgery by the American Board of Podiatric Surgery. A Fellow of the American College of Foot and Ankle Surgeons, he practices in Englewood, NJ.*

